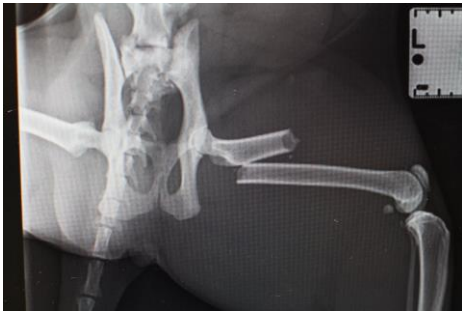


Patient report: Tigs – Fractured femur

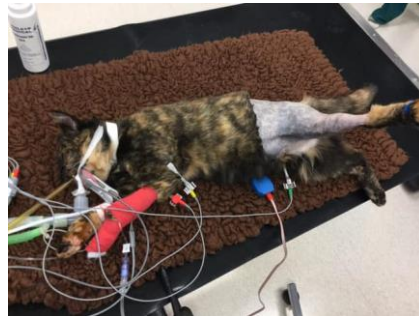Tigs is a 1 year old cat who was brought in to us after coming home non-weight bearing on her left hind leg. She was examined by our veterinary surgeon James Pattison who advised radiographs. These showed that Tigs had a transverse fracture of her left femur.

Tigs was taken to theatre and James placed an intramedullary pin through the bone and then applied a SOP (String of Pearls) plate to the femur.

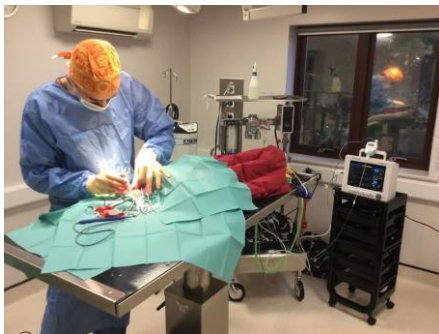Tigs made a good recovery from the surgery and was able to go home the following morning. She'll be crate rested for 6 weeks before we take more radiographs to see how the bone has healed.



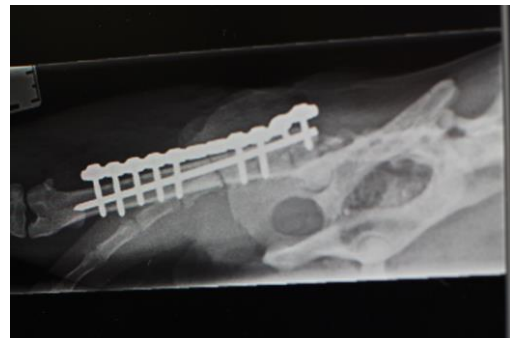Radiograph to assess the fracture



Surgery prep



James repairing the fracture



Radiograph post surgery



Tigs on her 2 day post op check